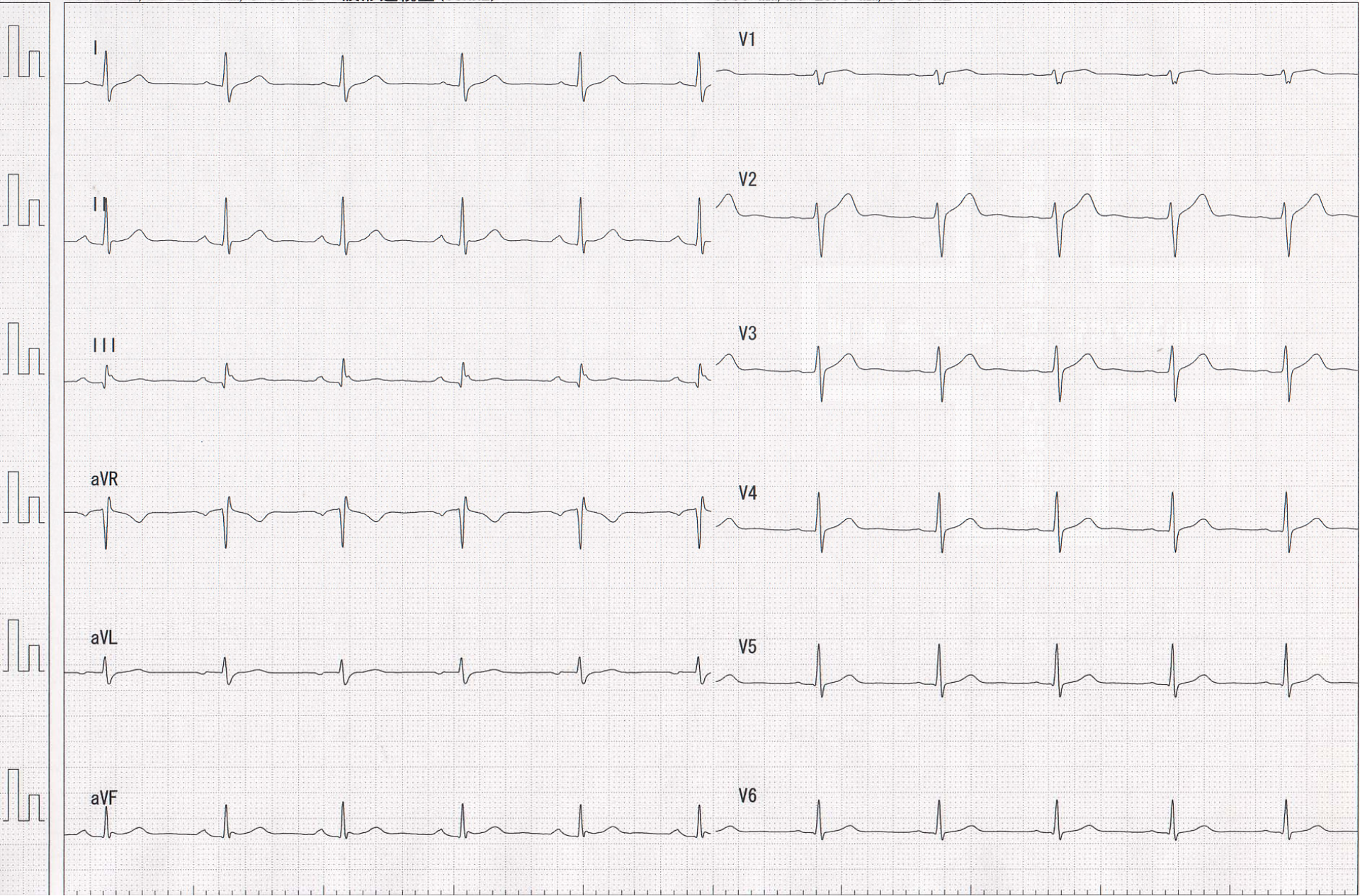


# Case 4 (1 st, Feb)

- 46 yrs-old, male
- This patient visited our emergency department to get the treatment for his tachycardia. Bolus injection of adenosine of 10mg was able to terminate his tachycardia. He denied to undergo radiofrequency catheter ablation at that moment. The incidence of his tachycardia attack increased for recent half a year, and he was determined to undergo catheter ablation.

# NSR Case 4





# PSVT Case 4

