



G-1 :43 yr F

【C.C】 Palpitation

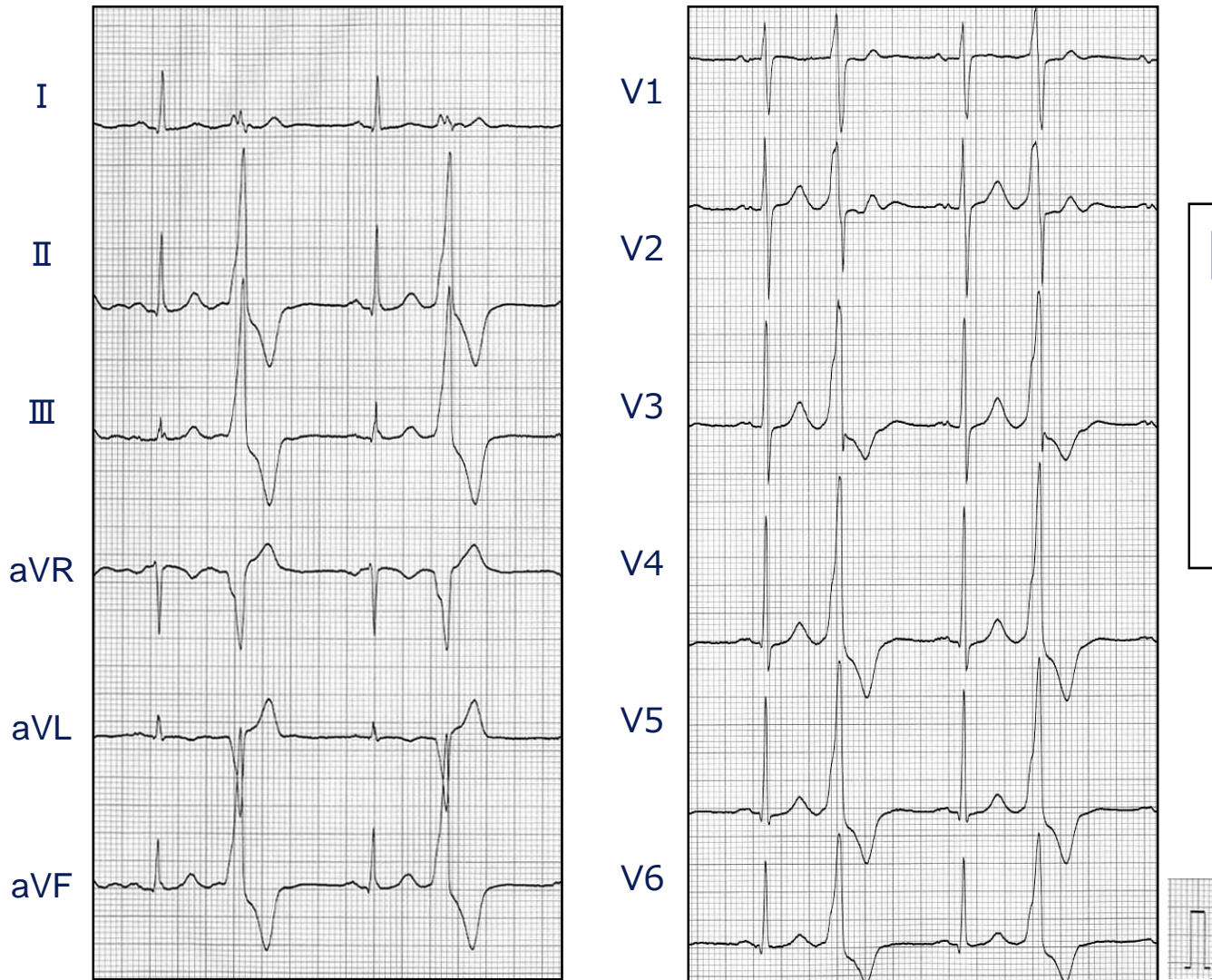
【Past. I】 Hypertension (since 2000, medication)

【Frequent VPCs】

She has palpitation since 2002. Her ECG had showed frequent VPC. Blocker was ineffective. So she was hospitalized in our hospital for catheter ablation.



12 leads ECG



Holter ECG

monomorphic VPC

34015/day

total QRS

105488/day